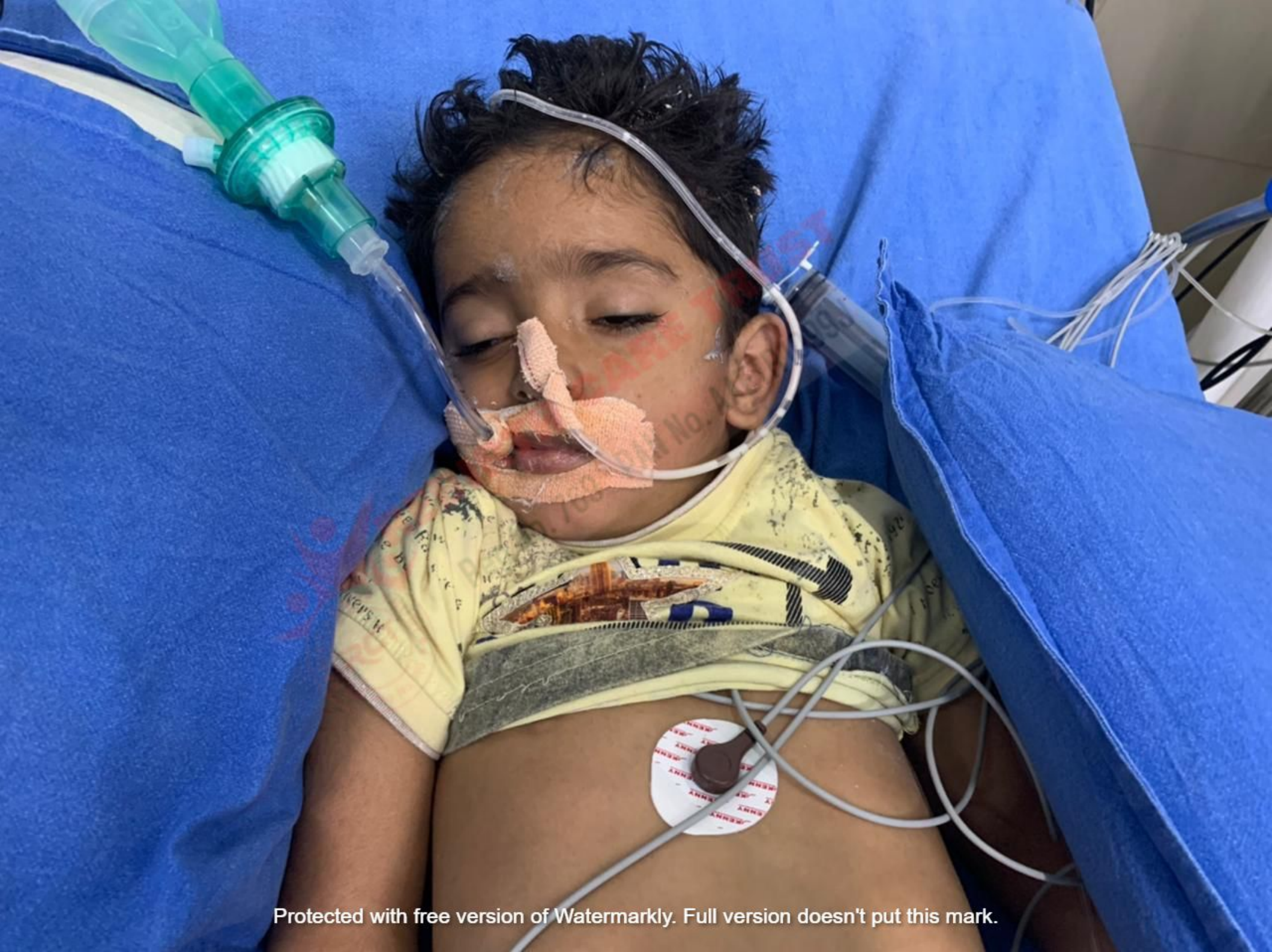





Girraj Ji Children Hospital

First Exclusive Pediatric Hospital in Gurugram



Opp. BSNL II Office, Car Market, Sector-12A, Gurugram - 122001 (Hr.)
Tel.: 9871869863 | Email : girrajchildrenhospital@gmail.com

CASE SUMMARY

Patient's Name	Master ARUSH	IPD No.	2071
S/O	RAGHVINDER	UHID	20/00 3381
Address	HANUMAN MANDIR RAJIV NAGAR	DOA	21-Apr-2022 11:49 PM
Age/Sex	4 Yrs/2 Months/27 Days /	CASE SUMMARY	30-Apr-2022 08:00 PM
Consultant Name	DR. MOHIT		
Contact No.			
Department/Specialty	PEDIATRICIAN & NEONATOLOGIST		

DIAGNOSIS

Cerebral Malaria / Encephalitis ? Autoimmune ?? Post viral.

PRESENTING COMPLAINTS

Fever for 4 days.

Loose stools for 4 days back.

Dullness for 1 day.

Alleged H/O abnormal behavior followed by staring and unresponsiveness and frothing from mouth 15 minutes back.

HISTORY OF PRESENTING ILLNESS

Baby had above mentioned complaints, for which seeking treatment outside, but as symptoms persisted, hence was brought to our center for further management.

EXAMINATION FINDING

GC Sick

Active Seizures present

SpO2 - 70% on room air, 94% on High flow

HR - 142/min

Chest - B/L Conducted sounds +

CVS - No murmur

P/A - soft

COURSE IN THE HOSPITAL

Child was admitted with above mentioned complaints, came in active seizures. Seizures aborted with Inj. Midazolam and Loading dose of Inj. Levera was given. Baby was started on high flow, IV Fluids, Antibiotics, Inj. Dexta, AED with other supportive care. Malaria antigen was positive for Plasmodium falciparum, hence Inj. Artesunate was added to ongoing treatment. Baby had recurrent seizures, hence loaded with Inj. Valparin and Inj. Gardenal and maintenance dose was continued. MRI Brain was S/O ? delayed/hypomyelination. EEG showed encephalopathy. In view of suspected autoimmune disorder Inj. Methylpred given. CSF postponed due to deteriorating clinical condition. Plan to do - repeat MRI, EEG, CSF autoimmune panel, serum MOG antibody panel. In view of deteriorating GCS baby was intubated and started on mechanical ventilation and IVIG was started. Repeat MRI was done s/o few, small, non-specific, ill defined subcortical white matter hyperintense foci in b/l frontal region. Parents updated.

TREATMENT GIVEN

High flow.

IVIG.

Inj. Monocef

Inj. Artesunate.

Inj. Gardenal

Inj. Valparin

Inj. Levera

Inj. Dexta

Inj. Methylpred

Inj. Doxy

Inj. PCM

IVIG

INVESTIGATION RESULT





Girraj Ji Children Hospital

First Exclusive Pediatric Hospital in Gurugram

Opp. BSNL II Office, Car Market, Sector-12A, Gurugram - 122001 (Hr.)
Tel.: 9871869863 | Email : girrajchildrenhospital@gmail.com



Date 01/05/2022

REQUISITION LETTER

To,
Rebirth care trust

Sub- Help the poor Mast. ARUSH (ID – 20/003381)

Respected Sir/Madam,

This is to certify that Mast. ARUSH (ID – 20/003381) is being treated at Girraj Ji Children Hospital since 24/04/2022.. The expected stay of baby is for another 3 weeks.

Parents are poor & unable to bare the expanses.

Expected expanses are Rs220,000/- to Rs 280,000/-

Please help the poor baby financially & oblige them. That shall be a great help for the parents.

Thanks

Dr Mohit Kumar Agrawal
Head NICU/PICU
Girraj Ji Children Hospital
Sector 12A Gurgaon





Girraj Ji Children Hospital

First Exclusive Pediatric Hospital in Gurugram



Opp. BSNL II Office, Car Market, Sector-12A, Gurugram - 122001 (Hr.)
Tel.: 9871869863 | Email : girrajchildrenhospital@gmail.com

CASE SUMMARY



Patient's Name	Master ARUSH	IPD No.	2071
S/O	RAGHVINDER	UHID	20/00 3381
Address	HANUMAN MANDIR RAJIV NAGAR	DOA	21-Apr-2022 11:49 PM
Age/Sex	4 Yrs/2 Months/27 Days /	CASE SUMMARY	30-Apr-2022 08:00 PM
Consultant Name	Dr. Mohit		
Contact No.			
Department/Speciality	PEDIATRICIAN & NEONATOLOGIST		

21-04-2022 CBC PROFILE TLC 10200 /Cu mm,21-04-2022 CBC PROFILE HAEMOGLOBIN 11.2 gm%,21-04-2022 CBC PROFILE DIFFERENTIAL LEUCOCYTE COUNT .,21-04-2022 CBC PROFILE Neutrophils 18 %,21-04-2022 CBC PROFILE Lymphocytes 70 %,21-04-2022 CBC PROFILE Eosinophils 01 %,21-04-2022 CBC PROFILE Monocytes 11 %,21-04-2022 CBC PROFILE Basophils 00 %,21-04-2022 CBC PROFILE R.B.C. Count 5.04 million/cu m,21-04-2022 CBC PROFILE P.C.V./HAEMATOCRIT 35.4 %,21-04-2022 CBC PROFILE MCV 70.2 fl.,21-04-2022 CBC PROFILE M C H 22.2 pg,21-04-2022 CBC PROFILE MCHC 31.6 g/dl,21-04-2022 CBC PROFILE PLATELET COUNT 2.50 lacs/cumm,21-04-2022 CBC PROFILE DIFFERENTIAL LEUCOCYTE COUNT .,21-04-2022 crp quantitative CRP QUANTITATIVE 4.01 mg/l,21-04-2022 KIDNEY FUNCTION TEST BLOOD UREA 11.36 mg/dL.,21-04-2022 KIDNEY FUNCTION TEST S. CREATININE 0.53 mg/dL.,21-04-2022 KIDNEY FUNCTION TEST S. POTASSIUM (K+) 4.21 m Eq/litre.,21-04-2022 KIDNEY FUNCTION TEST S. SODIUM (Na+) 139.1 m Eq/litre.,21-04-2022 KIDNEY FUNCTION

PATIENT CONDITION

At present, GC Sick.

On mechanical venilation, IV Fluids, antibiotics, antimalarial, AED and supportive treatment. Received IVIG.

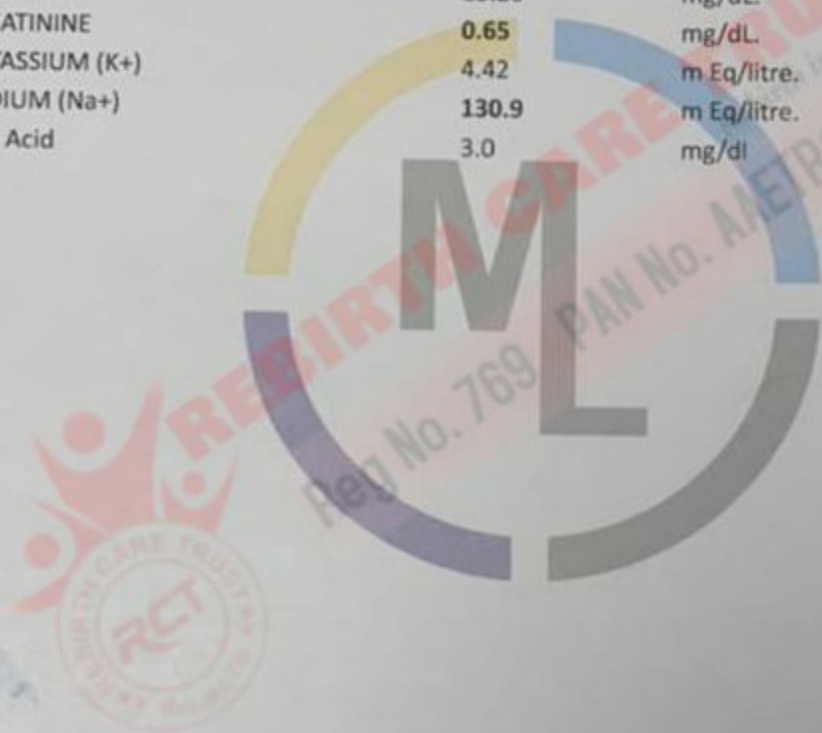Treating Consultant / Authorized Team Doctor	Name / Signature	 Dr. Mohit Kumar Agrawal MBBS, DNB (Pediatrics) HN-13926 Pediatrician & Neonatologist
Patient / Attendant	Name / Signature	
	Mobile No.	



UHID No : 3381	IPD No. 2071	Age/Sex : 4 Yrs/2 Months/27 Days / Male
Patient Name: Master ARUSH		Coll. Date : 27-Apr-2022 10:41 PM
Rep. By : DR MAYANK		Rep. Date : 27-Apr-2022 11:35 PM
Lab No : 2424		

BIOCHEMISTRY

Description	Result	Unit	Ref.Range
BLOOD UREA	15.26	mg/dL	10 - 50
S. CREATININE	0.65	mg/dL	0.7 - 1.4
S. POTASSIUM (K+)	4.42	m Eq/litre.	3.5 - 5.5
S. SODIUM (Na+)	130.9	m Eq/litre.	135 - 155
S. Uric Acid	3.0	mg/dl	2.4 - 7.0



[Signature]
TECHNICIAN

Dr. SWATI S. SIRI
[Signature]
MB, PATH
REG. NO. 46822
PATHOLOGIST

Not Valid for Medico Legal Purpose, partial reproduction of this report is not permitted.



UHID No : 3381 IPD No. 2071 Age/Sex : 4 Yrs/2 Months/27 Days / Male
Patient Name : Master ARUSH Coll. Date : 29-Apr-2022 06:24 AM
Rep. By : DR MOHIT Rep. Date : 29-Apr-2022 7:10AM
Lab No : 2424

BIOCHEMISTRY

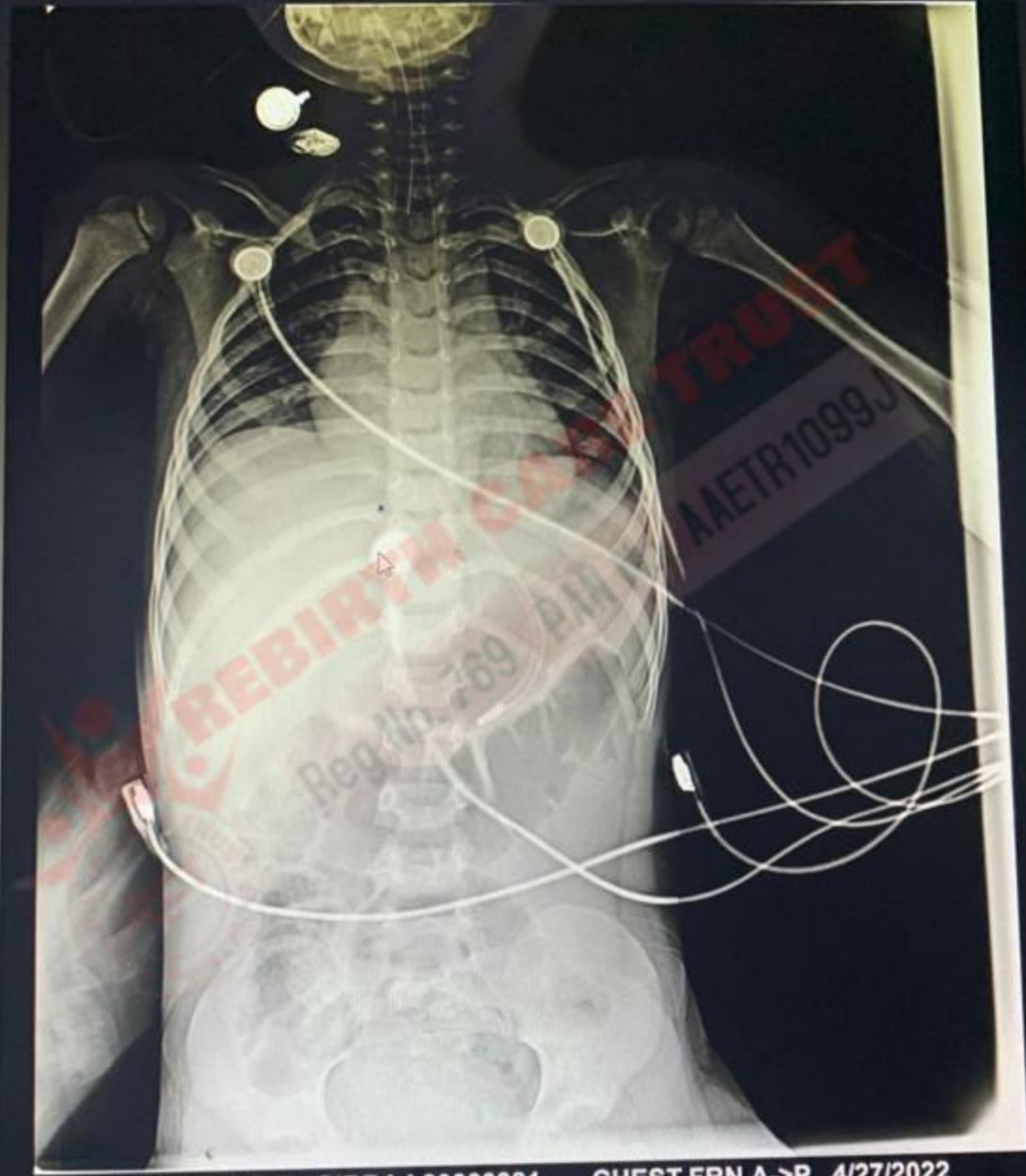Description	Result	Unit	Ref.Range
BLOOD UREA	16.6	mg/dL	10 - 50
S. CREATININE	0.45	mg/dL	0.7 - 1.4
S. POTASSIUM (K ⁺)	4.76	m Eq/litre.	3.5 - 5.5
S. SODIUM (Na ⁺)	137.0	m Eq/litre.	135 - 155
S. Uric Acid	4.17	mg/dl	2.4 - 7.0



TECHNICIAN

Dr. SWATI S. GIRI
MD-PATH
REGN NO. 46822
PATHOLOGIST

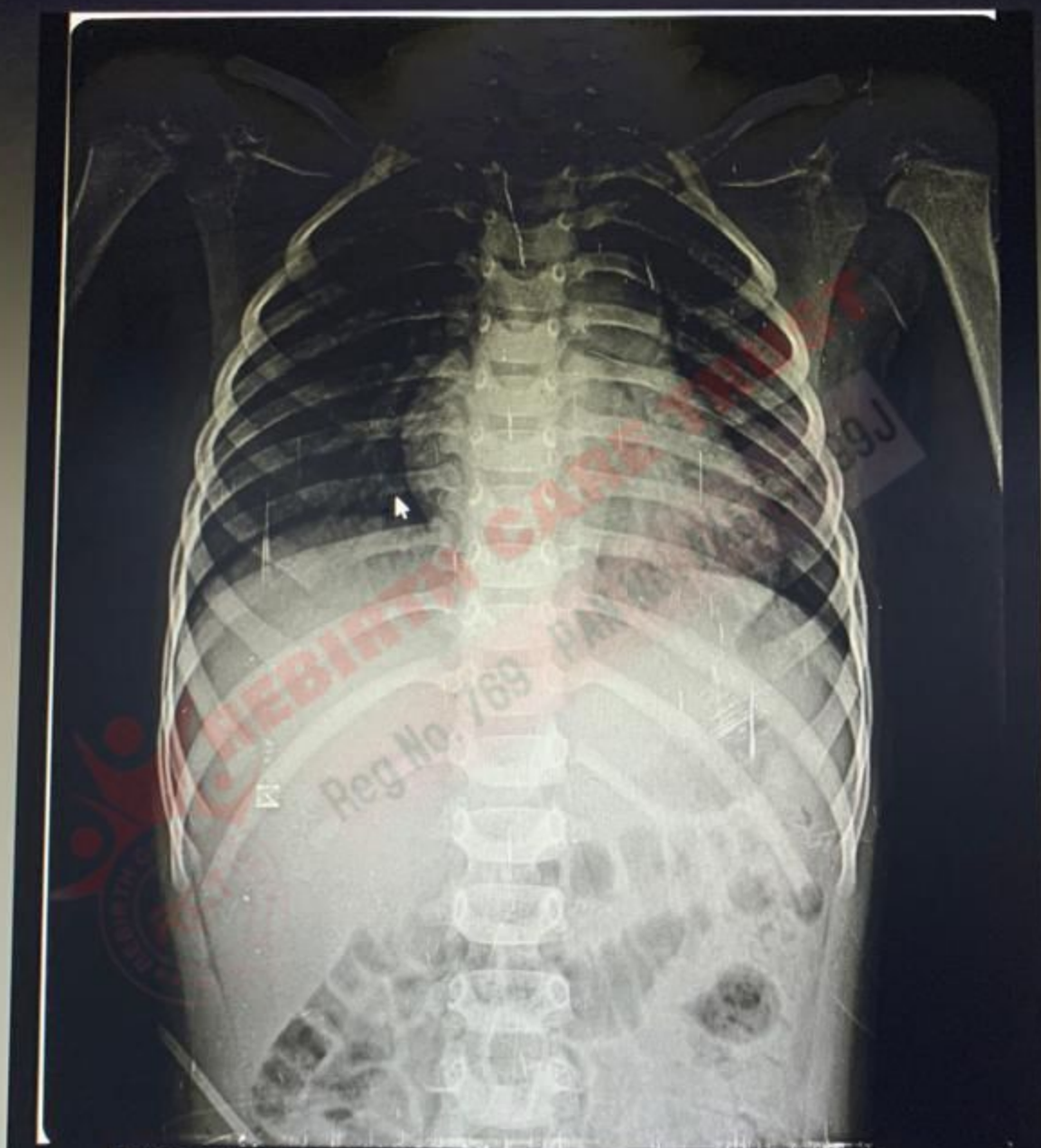Not Valid for Medico Legal Purpose, partial reproduction of this report is not permitted.



MAST. ARUSH GIRRAJ 20003381 CHEST,FRN A->P 4/27/2022
GIRRAJ JI CHILDREN HOSPITAL, SEC-12A, GURUGRAM

4280 X 3520

W: 941



MAST. ARUSH GIRRAJ 20003381 CHEST,FRN A->P 4/23/2022
GIRRAJ JI CHILDREN HOSPITAL, SEC-12A, GURUGRAM

015 X 2505

W: 941