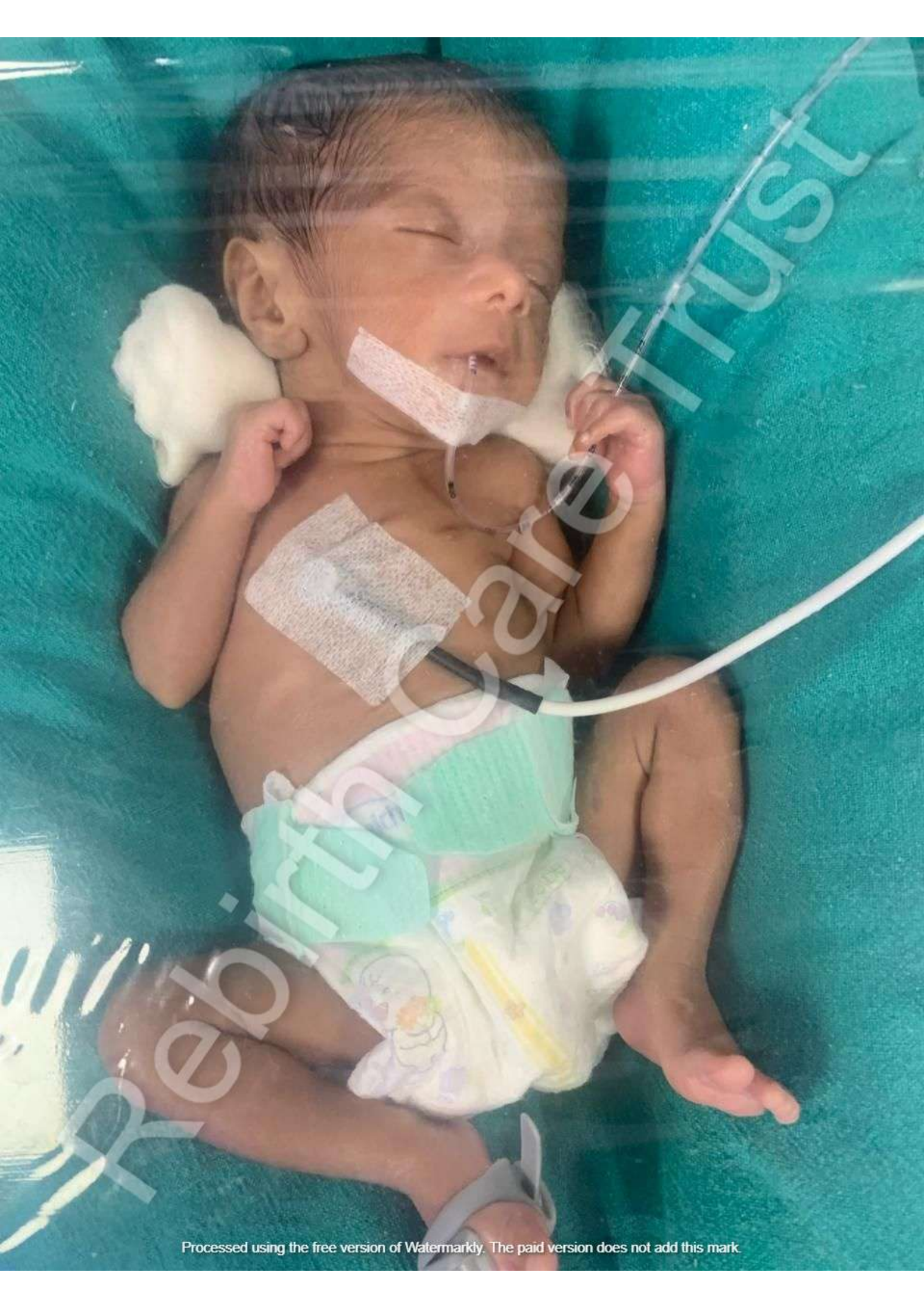





SILVER CREST HOSPITAL

4/9, Rattan Garden, New Colony Mor, Gurugram, Haryana-122001

Ph : 7303141112, E-mail : silvercresthospital@hotmail.com

Request Letter

To,

18-03-2024

Rebirth Cre Trust.

Subject: Help the poor B/O Anjali (ID: 1701)

Respected Sir/Madam.

This is to certify that B/O Anjali (ID: 1701) is being treated at Silver Crest Hospital since 08-02-2024 as a case of extreme premature 29 weeks, 1kg. The expected stay is for another 1 month. Parents are very poor and are unable to bare the expenses.

Expected expenses would be: 1.5 lacs

Please help the poor baby financially and oblige them. That shall be of great help to the parents.

Yours Truly.

Mayank Singh

Dr. Mayank Singh

Dr. Mayank Singh
M.B.B.S. MD Pediatrics
Fellowship in Neonatology
Regd. DMC 57733

Silver Crest Hospital.

SILVER CREST HOSPITAL
4/9, Rattan Garden, New Colony, Mor
Gurugram, Haryana-122001



Brij Anand Path Lab

Fully Computerised Lab

JAS-ANZ



Date	01/03/2024	Srl No.	17	Patient Id	24030117
Name	Adv. B/O ANJALI KUMARI	Age	22 Day	Sex	F
Ref. By	SILVER CREST HOSPITAL	UHID	2953		

Test Name	Value	Unit	Normal Value
COMPLETE HAEMOGRAM			
HAEMOGLOBIN (Hb)	12.0	gm/dl	11.0 - 16.5
TOTAL LEUCOCYTE COUNT (TLC)	7,730	/cumm	10000 - 25000
DIFFERENTIAL LEUCOCYTE COUNT (DLC)			
NEUTROPHIL	32	%	40 - 75
LYMPHOCYTE	57	%	20 - 45
EOSINOPHIL	03	%	01 - 06
MONOCYTE	08	%	02 - 10
BASOPHIL	00	%	0 - 0
R B C COUNT	3.29	Millions/cmm	3.0 - 5.4
P.C.V / HAEMATOCRIT	35.1	%	35 - 45
M.C.V	106.8	fl.	80 - 100
M.C.H	36.6	Picogram	27.0 - 31.0
M.C.H.C	34.3	gm/dl	33 - 37
PLATELET COUNT	2.34	Lakh/cmm	1.50 - 4.00

**** End Of Report ****

Dr. P. N. JAIN
M.D. PATHOLOGY
Reg. No. HR-HN-2142



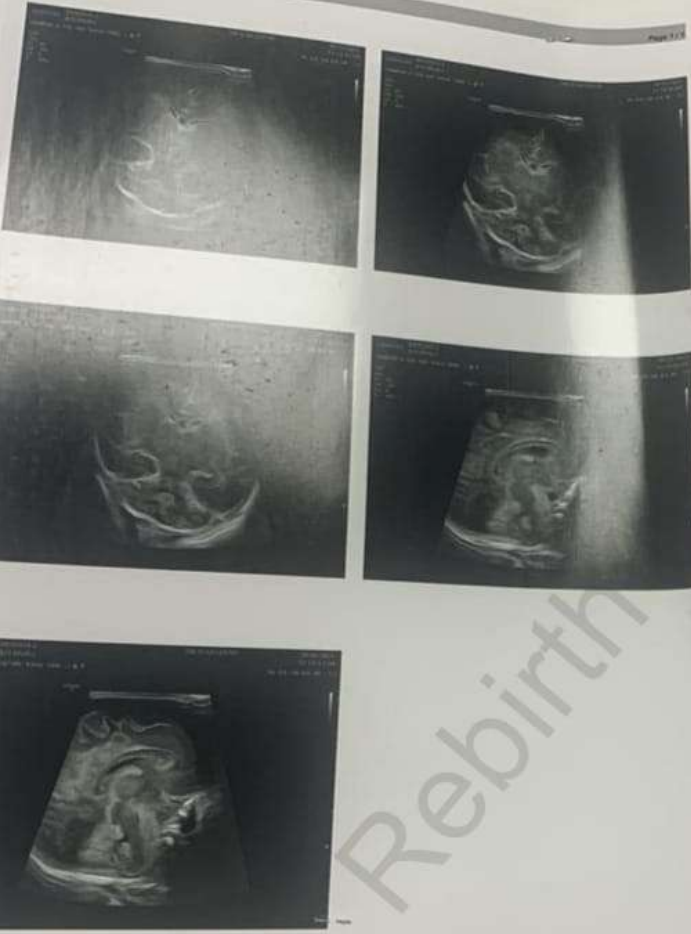**Lab Report & Home
Collection Delivery**

Digital X-ray, ECG, All Blood Test

5-6 Housing Board Colony Sec - 15, Jharsa Road,
Narayana Mother & Child Care Centre,
Near Bye Jyoti Hospital, Gurgaon Haryana - 122001
M.: 8860451314, 0124 - 4294177
E-mail : brijanandlab@gmail.com

(not valid for medico legal purpose.) brij anand path lab

(not valid for medico legal purpose.) brij anand path lab



011-262240000 - 262240001
 info@thescancentre.in
 www.thescancentre.in
 P-11, Lower ground floor, New Colony,
 Circular Road, Gurugram - 122001, Haryana

PATIENT NAME:	BABY OF ANJALI	AGE/SEX:	9 MONTH/MALE
REFD BY:	SILVER CREST HOSPITAL	DATE:	05-03-2024

USG REPORT - CRANIUM


OBSERVATION:

The study reveals normal gyral and sulcal pattern. No focal lesion is seen.
 Subependymal regions are normal on both sides. Bilateral caudo-thalamic grooves are normal.
 The lateral ventricles and third ventricles are normal. No evidence of hydrocephalus.
 The corpus callosum, thalami and brainstem are normal.
 The posterior fossa appears normal.
 Extra cerebral spaces appear normal. There is no evidence of fluid collection.

IMPRESSION:

- No significant abnormality seen.

Please correlate clinically.


 DR. ATISHI GUPTA
 M.B.B.S., M.D. (RADIO-DIAGNOSIS)
 CONSULTANT RADIOLOGIST



Timings: Daily 7 AM to 9 PM

3D / 4D Ultrasound | Colour Doppler | Fetal Echo | MRI
 Multislice CT SCAN | Low Dose Digital X-Ray | Biopsy
 FNAC | 2D Echo | TMT | PFT | ECG | All blood & lab test
 HSG | IVP | Barium studies | Health Check-Up



Brij Anand Path Lab

Fully Computerised Lab

JAS-ANZ



Date	04/03/2024	Srl No.	1	Patient Id	2403041
Name	Adv. B/O ANJALI KUMARI	Age	25 Day	Sex	F
Ref. By	SILVER CREST HOSPITAL	UHID	2953		

Test Name	Value	Unit	Normal Value
-----------	-------	------	--------------

CRP (QUANTITATIVE)	0.83	mg/L	(<5mg/L)
--------------------	------	------	----------

SEROLOGY

**** End Of Report ****

Dr. P.K. JAIN
M.D. PATHOLOGY
Reg. No. HR-HN-2142



**Lab Report & Home
Collection Delivery**

Digital X-ray, ECG, All Blood Test

5-6 Housing Board Colony Sec - 15, Jharsa Road,
Narayana Mother & Child Care Centre,
Near Bye Jyoti Hospital, Gurgaon Haryana - 122001
M.: 8860451314, 0124 - 4294177
E-mail : brijanandlab@gmail.com

(not valid for medico legal purpose.) brij anand path lab

Digital X-ray, ECG, All Blood Test

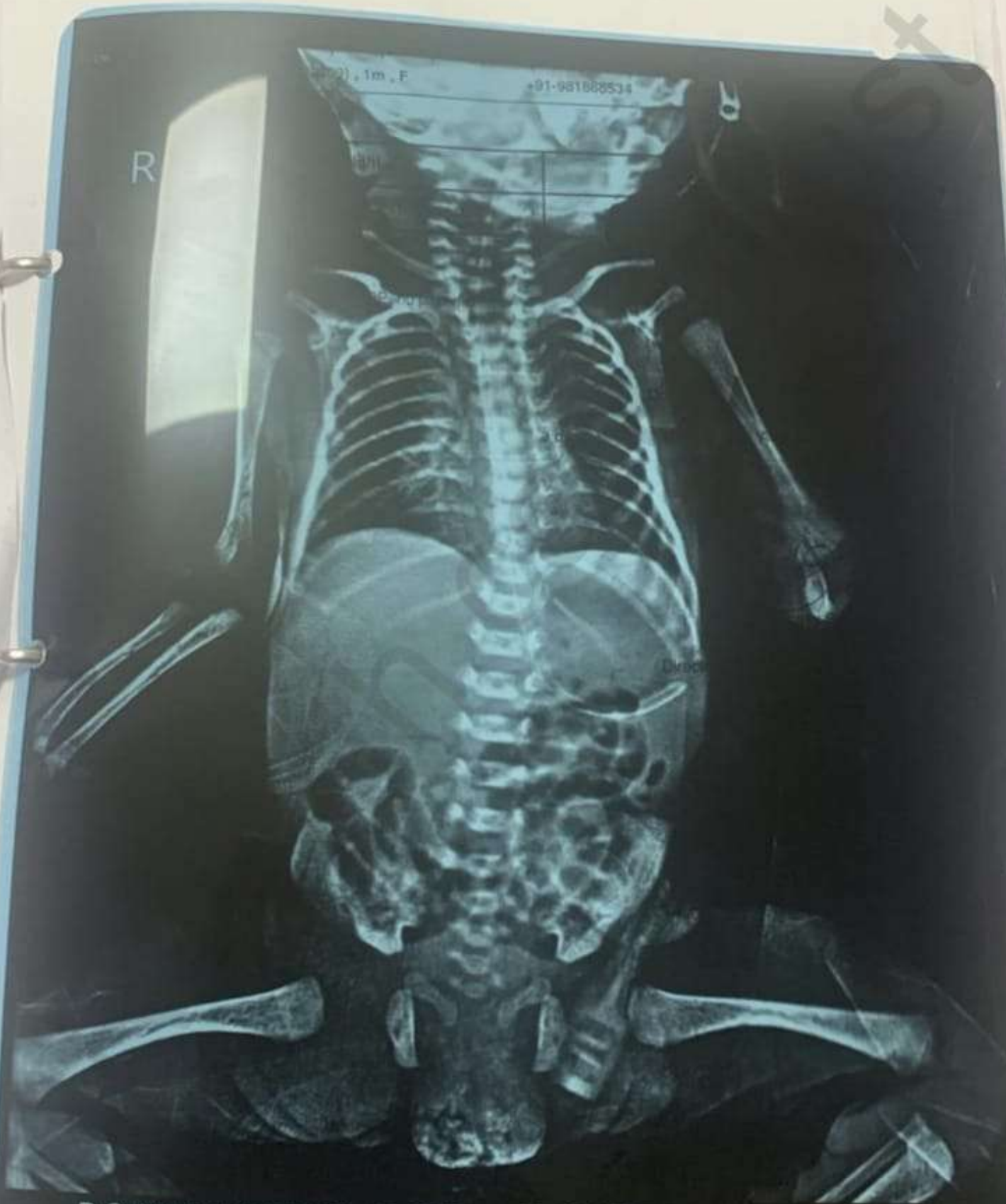(not valid for medico legal purpose.) brij anand path lab



Silver Crest Hospital

4/9, Rattan Garden, New Colony Mor, Gurugram, Haryana-122001

Ph : 7303141112, E-mail : silvercresthospital@hotmail.com



B O ANJALI KUMARI ID 2953 F CHEST.PA 2/8/2024 06:47 PM

SILVER CREST HOSPITAL GURUGRAM

Processed using the free version of Watermarkly. The paid version does not add this mark.



Silver Crest Hospital

4/9, Rattan Garden, New Colony Mor, Gurugram, Haryana-122001

Ph : 7303141112, E-mail : silvercresthospital@hotmail.com

Baby Of Anjali Kumari (#202409) , 1m , F

15-03-2024

Eye Examination

	Right eye	Left eye
Retina	Zone 2A Stage 2 ROP, no plus	Zone 2A Stage 2 ROP, no plus

Diagnosis

Both Eyes Zone 2 Anterior Stage 2 ROP, no plus disease

Rx

Medicine Name	Duration	Dosages	Instructions
DROPS MYCIN	3 day(s)	1 - 0 - 1	After food

Advice

Follow up after 1 week

Electronically Signed by:
Dr. Aparna Gupta
Director, Retina & ROP Specialist
9821007845
(Reg No.: 30779)
Ophthalmologist



SILVER CREST HOSPITAL

4/9, Rattan Garden, New Colony Mor, Gurugram, Haryana-122001
Ph : 7303141112, E-mail : silvercresthospital@hotmail.com

**NEORETINA
CLINICS**

Byo Anjane (F)

Dr. Aparna Gupta, MS

Director, Retina & ROP specialist
Reg. No. DMC-2017/344-014503

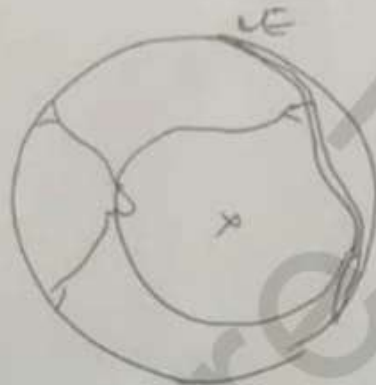
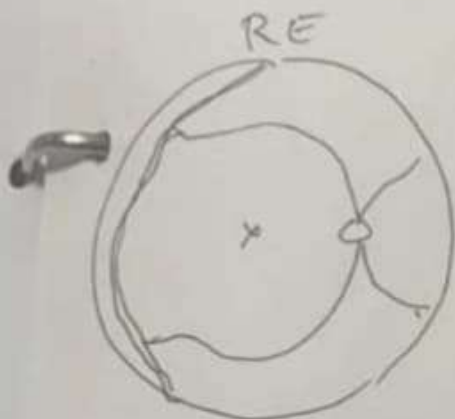
ROP screening report

DOB - 8/2/2024

GA - 29 wks

BM - 1 kg

CGA - 33 wks!



Zone 2 anterior
Stage 2 ROP
NO plus disease

Zone 2 Stage 2 ROP
NO plus disease

R
had Mycin 800
80 23d.

Rx 1 wk.

8/3/2024

WE ARE AT

Max Hospital Gurgaon | Cloud 9 Hospitals | Motherhood Hospital | Apollo Miracles | CK Birla Hospital | Park Hospital | Silver Crest Hospital | Triton Hospital, Kalkaji

e-mail: draparnagupta@neoretinaclinics.com



Brij Anand Path Lab

Fully Computerised Lab

JAS-ANZ



Date	09/03/2024	Sri No.	4	Patient Id	2403094
Name	Adv. B/O ANJALI KUMAR	Age	30 Day	Sex	F
Ref. By	SILVER CREST HOSPITAL	UHID	2953		

Test Name	Value	Unit	Normal Value
COMPLETE HAEMOGRAM			
HAEMOGLOBIN (Hb)	12.3	gm/dl	11.0 - 16.5
TOTAL LEUCOCYTE COUNT (TLC)	21,490	/cumm	10000 - 25000
DIFFERENTIAL LEUCOCYTE COUNT (DLC)			
NEUTROPHIL	25	%	40 - 75
LYMPHOCYTE	64	%	20 - 45
EOSINOPHIL	04	%	01 - 06
MONOCYTE	07	%	02 - 10
BASOPHIL	00	%	0 - 0
R B C COUNT	3.28	Millions/cmm	3.0 - 5.4
P.C.V / HAEMATOCRIT	33.4	%	35 - 45
M C V	101.8	fl.	80 - 100
M C H	37.4	Picogram	27.0 - 31.0
M C H C	36.7	gm/dl	33 - 37
PLATELET COUNT	5.91	Lakh/cmm	1.50 - 4.00

SEROLOGY

CRP (QUANTITATIVE)	0.73 mg/L	(<6mg/L)
--------------------	-----------	----------

**** End Of Report ****

Dr. P.K. JAIN
M.D. PATHOLOGY
Reg. No. HR-HN-2142



Lab Report & Home Collection Delivery

Digital X-ray, ECG, All Blood Test

5-6 Housing Board Colony Sec - 15, Jharsa Road
Narayana Mother & Child Care Centre
Near Bye Jyoti Hospital, Gurgaon Haryana - 122001
M.: 8860451314, 0124 - 429417
E-mail : brijanandlab@gmail.com

(not valid for medico legal purpose.) brij anand path lab